

## CASE REPORT

# A Phlebectasia of Internal Jugular Vein as a Manifestation of Chronic Cerebrospinal Venous Insufficiency in Meniere Syndrome Patients

Aldo Messina<sup>1</sup>, Cosimo Galletti<sup>2</sup>, Francesco Gazia<sup>3</sup>, Francesco Ciodaro<sup>4</sup>, Alessandro Corvaia<sup>5</sup>, Davide Piraino<sup>6</sup>, Bruno Galletti<sup>7</sup>

## ABSTRACT

Cerebral and ear flow with possible anomalies should cause a chronic cerebrospinal venous insufficiency, analyzed by echo color Doppler ultrasound examination in patients with Meniere disease. The current classification of the International Society for Neurovascular Disease considers the venous anomalous outflow as an endovascular and/or compressive syndrome proposing a corresponding treatment. We present a case of a patient with Meniere disease with phlebectasia of the internal jugular vein, a condition not described in the current classification. Phlebectasia should be a possible mechanism of anomalous venous outflow, giving us the possibility to introduce a new treatment for these patients and reinforcing the concept that echo-Doppler of jugular and vertebral veins should be a routine examination in patients with Meniere disease.

**Keywords:** Chronic cerebrospinal venous insufficiency, Echography, Ectasia, Jugular vein, Meniere disease.

*Otorhinolaryngology Clinics: An International Journal* (2022): 10.5005/jp-journals-10003-1422

## INTRODUCTION

Internal jugular vein (IJV) and vertebral vein (VV) system is the main protagonist of cerebral and ear outflow<sup>1</sup> and plays a possible significant role in many diseases of the head the neck. Echo Color Doppler Ultrasound (ECDUS) analysis and/or magnetic resonance imaging (MRI) and invasive methods, such as phlebography, are recommended in the recent literature for evaluating extracranial venous abnormalities.<sup>2</sup> These methods and the entrance of cerebral and ear venous system drainage analysis in the clinical practice have clarified two significant points:

- The arterial system needs an evaluation when the specialist investigates the cerebral and ear system, but the venous system is a relevant component too.
- Cerebral and ear drainage with possible anomalies should cause a chronic cerebrospinal venous insufficiency (CCSVI), one of the investigations to realize when the specialist analyzes the causes of cerebral and ear diseases.

Mandolesi et al. reported classification of CCSVI in three different patterns:<sup>3</sup> type I CCSVI due to an endovascular obstacle, as a septum, annulus stenosis, twisted or hypoplasia of venous segment(s), hypomobile valve flap, with a final flow obstacle<sup>4</sup> called "hydraulic"; type II CCSVI due to a muscular compression without endovascular anomalies, called "mechanical"; and type III CCSVI presenting both endovascular and extravascular anomalies, called "mixed."

Each pattern of CCSVI has a different treatment option: percutaneous transluminal angioplasty for endovascular anomalies<sup>5</sup> or intervention for sternocleidomastoid (SCM) and omohyoid (OM) muscle compression of IJV (J2–J3 segments mainly) performing a muscular resection<sup>6,7</sup> or through a conservative as well as effective treatment described first by our team.<sup>8</sup> In the past few years, the involvement of an anomalous IJV and VV outflow in ear disease and in particular in patients with Meniere disease (MD) was deeply

<sup>1,5</sup>Audiology Section, University Hospital "P Giaccone", Palermo, Italy

<sup>2–4,7</sup>Department of Adult and Development Age Human Pathology "Gaetano Barresi", Unit of Otorhinolaryngology, University of Messina, Messina ME, Italy

<sup>6</sup>Audiology Section and Interventional Cardiology Unit, University Hospital "P Giaccone", Palermo, Italy

**Corresponding Author:** Cosimo Galletti, Department of Adult and Development Age Human Pathology "Gaetano Barresi", Unit of Otorhinolaryngology, University of Messina, Messina ME, Italy, e-mail: cosimogalletti92@gmail.com

**How to cite this article:** Messina A, Galletti C, Gazia F, et al. A Phlebectasia of Internal Jugular Vein as a Manifestation of Chronic Cerebrospinal Venous Insufficiency in Meniere Syndrome Patients. *Int J Otorhinolaryngol Clin* 2022;14(1):42–46.

**Source of support:** Nil

**Conflict of interest:** None

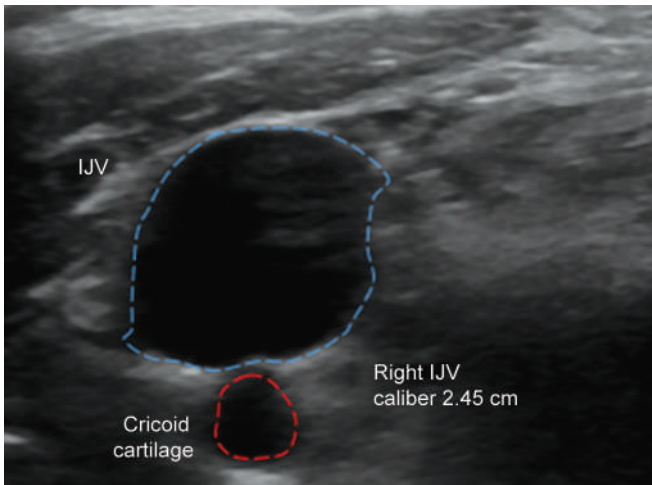
investigated. We present a case of a patient with Meniere syndrome diagnosed 5 years ago, in whom, during the ECDUS examination, the CCSVI form observed is sometimes not related to any pattern of literature classification.

## CASE DESCRIPTION

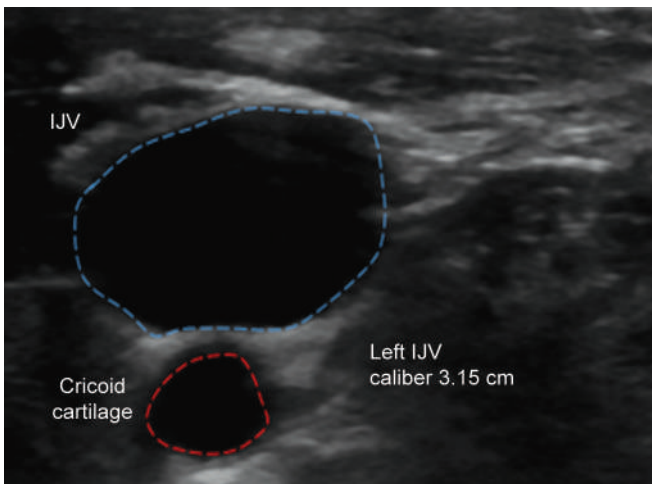
In our Audiology Department, patients with MS follow a diagnostic process that includes a physical examination, tonal and vocal audiometry, impedance measurement looking for jugulotympanic reflex evaluating middle ear acoustic status,<sup>9</sup> and ECDUS to investigate whether there is an anomalous cerebral and ear outflow.

During the ECDUS examination, the CCSVI form observed is sometimes not related to any pattern of literature classification, not allowing an adequate treatment for these patients.

We present a case of a 57-year-old man who was admitted to our Audiology Department for MS diagnosed 5 years ago with tinnitus, fullness, and a progressive hearing loss in both ears mainly in the last 2 years, confirmed by an audiometric examination. Previous medical treatments performed with betahistine and corticosteroids did not give effective and durable benefits to his condition. Ear computed tomography was negative for any pathologies, as well as the impedance measurement and other examinations. ECDUS analysis revealed an anomalous venous outflow because the bilateral IJV caliber showed a considerable ectasia in J2 and J1 segments (Figs 1 and 2), associated with a low or absent flow (Fig. 3), in the absence of endovascular anomalies and/or muscle entrapment. J3 segments showed a normal caliber, confirmed by the imperceptible soft swelling, not tender and not pulsatile, in the anterior down neck region mainly during swallowing and Valsalva maneuver.

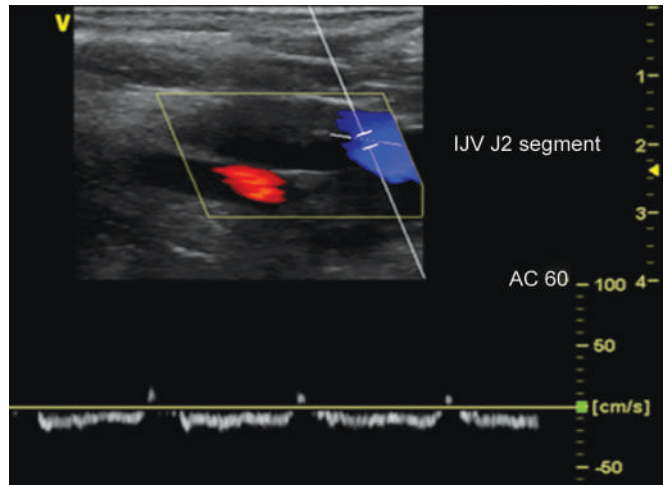


**Fig. 1:** CSA of right IJV showing a phlebectasia (caliber of 2.45 cm) in J2 and J1 segments, during ECDUS examination in the absence of endovascular anomalies and/or muscle compression



**Fig. 2:** CSA of left IJV showing a phlebectasia (caliber of 3.15 cm) in J2 and J1 segments, during ECDUS examination in the absence of endovascular anomalies and/or muscle compression

Electrocardiogram and echocardiography were performed to exclude an IJV ectasia secondary to heart failure and/or pulmonary



**Fig. 3:** Low venous outflow in J2 segments of IJV (<20 cm/second). Blue color represents the signal that is moving away, and red color represents the signal that is approaching

hypertension, while a detailed physical examination and an ECDUS of lower limbs confirmed venous insufficiency with ectasia and reflux of saphenous veins, occasionally treated by elastic stockings.

### Ethical Approval

All procedures performed in studies involving the patient were following the ethical standards of the institutional and/or national research committee and with the 1964 Helsinki declaration and its later amendments or comparable ethical standards. The study was approved by the Ethics Committee of the University of Palermo on August 27, 2019, with protocol number 84/19.

### DISCUSSION

Meniere disease is an idiopathic syndrome of endolymphatic hydrops characterized by typical symptoms, such as dizziness, progressive hearing impairment, tinnitus, and a sensation of fullness in the ear.<sup>10</sup>

Despite the origin of this syndrome being still unknown and the most accredited hypothesis is a multifactorial origin, the syndrome should be an inability of the inner ear to absorb endolymph, due to a final hydraulic mechanism, leading to endolymphatic hydrops.<sup>11</sup> The Committee on Hearing and Equilibrium Guidelines for the Diagnosis and Evaluation of Therapy in Meniere disease describes this pathology as “a clinical disorder defined as the idiopathic syndrome of endolymphatic hydrops”.<sup>10</sup>

In 1972, Godlowski has hypothesized the possible role of capillaries and venous of the stria vascularis.<sup>12</sup> In MD patients, an elevation of hydrostatic head pressure of stria vascularis microcirculation could determine an imbalance between endolymphatic secretion in the cochlea and endolymph resorption by the endolymphatic sac due to an increased force, which drives fluid from the capillaries into the endolymphatic space.

Godlowski has suggested a possible pathogenetic mechanism based on which this excessive endolymphatic volume in the endolymphatic space could be the consequence of an anomalous, altered, and/or hindered venous ear outflow composed primarily of IJV and VV veins through anterior and posterior vestibular veins and/or of the cochlear veins.

The quality of life of MD patients is subjected to considerable stress because of continuous or fluctuating tinnitus during all

their activities and during the night, as well as vertigo episodes often associated with nausea and vomiting and other vasovagal symptoms, initially monolateral and consequently completed by a hearing capacity progressive degeneration.

MD patients usually undergo numerous medical investigations to clarify the factors involved in their syndrome to obtain an adequate treatment option. In 2014, a position statement of the International Society for Neurovascular Disease,<sup>2</sup> signed by four expert panel committees, including more than 60 neurology, radiology, vascular surgery, and interventional radiology specialists, recommended the ECDUS as the gold-standard examination to clarify the cerebral and ear venous outflow. ECDUS is noninvasive and of low cost, with real-time high-resolution images, giving information about cross-sectional area (CSA), intraluminal defects, and/or venous segment compression and blood flow parameters.<sup>13</sup> ECDUS could be considered a routine examination in patients with neurological and/or ear disorders<sup>2</sup> to evaluate the presence or not of CCSVI.

In the past few years, the possible relation between CCSVI and neurological and ear disorder was investigated, founding a possible contributing factor and common etiopathogenetic mechanism in several diseases, such as multiple sclerosis (MS),<sup>14–16</sup> migraine,<sup>17,18</sup> Alzheimer syndrome, and/or Parkinson disease<sup>19,20</sup> and MD.

Bavera et al. have analyzed the possible role of CCSVI as an expression of different patterns in the same background of different pathologies as MS and MD.<sup>21</sup>

They observed that CCSVI is present in a significant percentage of these patients but with different patterns. In MS and MD patients, there are different involved segments and a different role of VV as a compensatory collateral way, by underlining how this anomalous venous outflow could represent a common anatomical condition that promotes these two cerebral and ear pathologies or common substrate as a trigger for other multifactorial mechanisms.

In MD, the role of CCSVI as “lead actor or co-star” in the genesis of endolymphatic hydrops should be related to an excess of endolymphatic volume, secondary to an anomalous and perpetuate over time venous drainage of vestibular veins and/or of the cochlear veins into the IJV and VV. Congenital and/or acquired anatomical anomalies and/or blood flow alterations therefore could represent a predisposing factor. Genetic predisposition, inflammation or endocrine factors, autoimmunity, neuro-vegetative abnormalities, viral infection, dietary deficiencies altering the equilibrium between ion transports, endolymph composition, and volume development could promote an endolymphatic hydrop and the MD consequently.

Filippo et al. investigated the venous outflow of the inner ear in patients with MD considering that venous anomalies typical for CCSVI do not allow physiological endolymphatic drainage.<sup>22</sup> They compared a group of MD patients with a control group of healthy patients, observing a statistically significant presence of CCSVI in the MD patients. They observed two different and consequential mechanisms that occurred in the early stage of MD, when the symptoms are not persistent, but fluctuating and in the late stage of this syndrome, during chronicity of the symptoms, both linked to endolymphatic hydrop.

Bruno et al. analyzed one hundred and eighty-two patients with MD unresponsive to standard treatment, performing the ECDUS examination and finding the CCSVI criteria in 87.5% MD patients and 12% of the control group.<sup>23</sup> They performed phlebography and venous angioplasty explained previously as a treatment option.<sup>5</sup> The immediate results and a follow-up of 24 months underlined an improvement of symptoms and quality of life that the patients maintained during life.

Nowadays, venoplasty is not the only treatment option for MD patients with CCSVI criteria, because in the past few years it has been just proposed different approaches according to the CCSVI found patterns based on Mandolesi classification.

Our team has proposed a flow chart describing the diagnosis and a different approach to all three CCSVI patterns.<sup>24</sup> An adequate and programmed approach is necessary to obtain significant results in terms of improving quality of life and decrease in symptoms. Moreover, we proposed a detailed description of physiotherapy cycle treatment in the case of IJV entrapment in CCSVI patterns II and III, due to a muscular compression by SCM and OM muscles, as indicated previously<sup>8</sup> as an alternative to surgical option previous described in the literature.<sup>7</sup>

Our team describes one of the many patients transiting through our unit with a CCSVI pattern not classified yet, showing an anomalous IJV and VV outflow due to a phlebectasia caliber and a consequently altered low or absent flow. The literature describes only a few cases of phlebectasia,<sup>25,26</sup> as a differential diagnosis of swelling in the neck (laryngocele, cystic hygroma, branchial cyst, and superior mediastinal mass) and excluding an ectasia due to a right heart complication and/or pulmonary hypertension. This condition described in the literature is mainly observed as single side (and not usually bilateral as described in our patient) in pediatric ages or young adults, and after ECDUS confirmation, conservative follow-up is usually recommended because the literature neither describes complications nor analyzes the possible role of low and/or anomalous flow and consequently CCSVI.

Our team describes the phlebectasia of bilateral IJV and the role in CCSVI due to a low or absent and anomalous flow (Fig. 1), not secondary to a right heart complication or pulmonary hypertension. It is associated with venous insufficiency of lower limbs, a potential hypothesis to confirm:

- The CCSVI could be sometimes the expression of a systemic venous insufficiency rather than an alteration of a single system, involving not only the cerebral and ear district but also the lower limbs too;
- Lower limb insufficiency is deeply analyzed, and many treatment options are described for the patients; cerebral and ear venous system should be a district of interest too.

Patients with advanced binaural involvement with Meniere disease may present a challenge to conventional criteria for cochlear implant candidacy for the fluctuating symptoms and severe-to-profound sensorineural hearing loss. Further, previous vestibular

**Table 1:** Messina-Piraino new complete classification of anomalous cerebral and ear venous outflow

Pattern	Characteristics	Name
Type I	Reduced CSA due to endovascular obstacle(s)	Hydraulic form
Type II	Reduced CSA or complete muscular compression by SCM and/or OM muscles	Mechanical form
Type III	Reduced CSA due to both endovascular and extravascular anomalies	Mixed compressive form
Type IV	Ectasic CSA in absence of muscular compression and/or venous anomalies with a reduced/absent or low flow	Ectasic form



surgery, including labyrinthectomy, does not contraindicate cochlear implantation.<sup>27-29</sup>

We propose a new classification of CCSVI by integrating the fourth pattern in the three patterns described by Mandolesi et al.<sup>3</sup> because the phlebectasia is not contemplated yet (Table 1). This medical condition requires appropriate deepening not only in terms of incidence in patients with cerebral and ear anomalous venous outflow, but also to propose an adequate treatment option. As in other districts as lower limbs, the anomalous venous outflow of the ear and cerebral district cannot be considered only a compressive syndrome, but a larger concept, including both anomalies, a narrowing or ectasia caliber, determining an altered venous system, and need a treatment option.

## CONCLUSION

Echo color Doppler ultrasound of IJV and VV should be a routine examination in patients with audiological symptoms of MD. Current CCSVI classification describes venous outflow patterns and treatment options but needs to consider and include the phlebectasia of IJV, filling a gap not only as a possible mechanism of anomalous venous outflow but mainly in terms of tailored treatment for these patients.

## ORCID

Cosimo Galletti  <https://orcid.org/0000-0002-7226-4596>

## REFERENCES

- Zamboni P, Galeotti R. The chronic cerebrospinal venous insufficiency syndrome. *Phlebology* 2010;25(6):269–279. DOI: 10.1258/phleb.2010.009083.
- Zivadinov R, Bastianello S, Dake DM, et al. Recommendations for multimodal noninvasive and invasive screening for detection of extracranial venous abnormalities indicative of chronic cerebrospinal venous insufficiency: a position statement of the International Society for Neurovascular Disease. *J Vasc Interv Radiol* 2014;25(11):1785–1794. DOI: 10.1016/j.jvir.2014.07.024.
- Mandolesi S, D'Alessandro A, Ciccone MM, et al. Analysis of patients with chronic cerebro-spinal venous insufficiency and multiple sclerosis: identification of parameters of clinical severity. *Veins Lymphatics* 2015;4(4). DOI: 10.4081/vl.2015.4570.
- Zamboni P, Morovic S, Menegatti E, et al. Screening for chronic cerebrospinal venous insufficiency (CCSVI) using ultra-sound-recommendations for a protocol. *Int J Angiol* 2011;30:571–597. PMID: 22233619.
- Piraino D, Andolina G, Messina A. Truncular venous malformations in Ménière disease patients: the key for a new treatment perspective? *J Vasc Interv Radiol* 2016;27(5):766–768. DOI: 10.1016/j.jvir.2016.01.141.
- Frau GN, Pagani R, Agarwal N, et al. The role of omohyoid muscle entrapment of the internal jugular vein and is surgical transection in Ménière's disease and other inner ear disorders. *Veins Lymphatics* 2019;8(2):8431. DOI: 10.4081/vl.2019.8431.
- Zamboni P, Menegatti E, Cittanti C, et al. Fixing the jugular flow reduces ventricle volume and improves brain perfusion. *J Vasc Surg Venous Lymphat Disord* 2016;4(4):434–445. DOI: 10.1016/j.jvsv.2016.06.006.
- Piraino D, Garofalo G, Faletra A, et al. The omohyoid and sternocleidomastoid muscles entrapment of the internal jugular vein: which role in Ménière disease patients? Treatment perspective description. *Veins Lymphatics* 2018;7(3):7760. DOI: 10.4081/vl.2018.7760.
- Magnano M, Albera R, Lacilla M, et al. Impedance measurement as a noninvasive technique for the monitoring of intracranial pressure variations. *Audiology* 1994;33(4):237–243. DOI: 10.3109/00206099409071883.
- Committee on Hearing and Equilibrium guidelines for the diagnosis and evaluation of therapy in Meniere's disease. American Academy of Otolaryngology-Head and Neck Foundation, Inc. *Otolaryngol Head Neck Surg* 1995;113(3):181–185. DOI: 10.1016/S0194-5998(95)70102-8.
- Schuknecht HF, Gulya AJ. Endolymphatic hydrops—an overview and classification. *Ann Otol Rhinol Laryngol* 1983;106:1–20. DOI: 10.1177/00034894830920s501.
- Godlowski Z. Hyperosmosis of endolymph as primary pathogenic mechanism of Meniere's disease and its clinical management. *Acta Otolaryngol Suppl* 1972;299:1–36. PMID: 4272470.
- Zamboni P, Galeotti R, Menegatti E, et al. Chronic cerebrospinal venous insufficiency in patients with multiple sclerosis. *J Neurol Neurosurg Psychiatry* 2009;80(4):392–399. DOI: 10.1136/jnnp.2008.157164.
- Traboulsee AL, Knox KB, Machan L, et al. Prevalence of extracranial venous narrowing on catheter venography in people with multiple sclerosis, their siblings, and unrelated healthy controls: a blinded, case-control study. *Lancet* 2014;383(9912):138–145. DOI: 10.1016/S0140-6736(13)61747-X.
- Zivadinov R, Lopez-Soriano A, Weinstock-Guttman B, et al. Use of MR venography for characterization of the extracranial venous system in patients with multiple sclerosis and healthy control subjects. *Radiology* 2011;258(2):562–570. DOI: 10.1148/radiol.10101387.
- Zamboni P. Intraluminal jugular septation. *Ann Neurol* 2010;68(6):969. DOI: 10.1002/ana.22152.
- Chou CH, Chao AC, Lu SR, et al. Cephalic venous congestion aggravates only migraine-type headaches. *Cephalalgia* 2004;24(11):973–979. DOI: 10.1111/j.1468-2982.2004.00781.x.
- Paparella MM. The cause (multifactorial inheritance) and pathogenesis (endolymphatic malabsorption) of Ménière's disease and its symptoms (mechanical and chemical). *Acta Otolaryngol* 1985;99(3-4):445–451. DOI: 10.3109/00016488509108936.
- Chung CP, Beggs C, Wang PN, et al. Jugular venous reflux and white matter abnormalities in Alzheimer's disease: a pilot study. *J Alzheimer's Dis* 2014; 39(3):601–609. DOI: 10.3233/JAD-131112.
- Liu M, Xu H, Wang Y, et al. Patterns of chronic venous insufficiency in the dural sinuses and extracranial draining veins and their relationship with white matter hyperintensities for patients with Parkinson's disease. *J Vasc Surg* 2015;61(6):1511.e1–1520.e1. DOI: 10.1016/j.jvs.2014.02.021.
- Bavera PM, Di Bernardino F, Cecconi P, et al. Chronic cerebro-spinal insufficiency in multiple sclerosis and meniere disease: same background, different patterns? *Veins Lymphatics* 2017;6:6533. DOI: 10.4081/vl.2017.6533.
- Filippo R, Ciciarello F, Attanasio G, et al. Chronic cerebrospinal venous insufficiency in patients with Meniere's disease. *Eur Arch Otorhinolaryngol* 2015;272(1):77–82. DOI: 10.1007/s00405-013-2841-1.
- Bruno A, Napolitano M, Califano L, et al. The prevalence of chronic cerebrospinal venous insufficiency in meniere disease: 24-month follow-up after angioplasty. *J Vasc Interv Radiol* 2017;28(3):388–391. DOI: 10.1016/j.jvir.2016.10.019.
- Messina A, Garofalo G, Faletra A, et al. Three patterns of chronic cerebrospinal venous insufficiency in Meniere syndrome patients: diagnosis and treatment options. *Veins Lymphatics* 2020;9(1):8758. DOI: 10.4081/vl.2020.8758.
- Cheah SC, Wong HT, Lau CY. Rare left-sided presentation of internal jugular vein ectasia in an adult. *Ann Saudi Med* 2018;38(5):381–382. DOI: 10.5144/0256-4947.2018.381.
- Kesarwani A, Goyal A, Kumar A. Phlebectasia of Internal Jugular vein—a rare differential case of neck swelling with review of literature. *Iran J Otorhin* 2019;31(105):239–242. PMID: 31384591.
- Galletti F, Cammaroto G, Galletti B, et al. Technetium-99m (<sup>99m</sup>Tc)-labelled sulesomab in the management of malignant external otitis: is there any role? *Eur Arch Otorhinolaryngol* 2015;272(6):1377–1382. DOI: 10.1007/s00405-014-2938-1.

28. Ciodaro F, Freni F, Alberti G, et al. Application of cervical vestibular-evoked myogenic potentials in adults with moderate to profound sensorineural hearing loss: a preliminary study. *Int Arch Otorhinolaryngol* 2020;24(1):e5–e10. DOI: 10.1055/s-0039-1697988.
29. Ciodaro F, Freni F, Mannella VK, et al. Use of 3D volume rendering based on high-resolution computed tomography temporal bone in patients with cochlear implants. *Am J Case Rep* 2019;20:184–188. DOI: 10.12659/AJCR.914514.

